

LOCALISED EPIPHYSEAL DYSPLASIAS (Report of six cases)

Kozłowski K.,¹ Maroteaux P.,² Nicol RO.,³ Scougall JS⁴

Departments of Radiology¹ and Orthopaedics⁴ New Children's Hospital, Westmead (Sydney), Australia; Department of Genetics, Hopital des Enfants Malades, Paris, France², and Eastwood Orthopaedic Clinic, Auckland, New Zealand³

Abstract

Localised bone dysplasias constitute a group of disorders in which one anatomical area shoulders, elbows, hips, spine, hands or feet is affected. Borderline or minimal skeletal anomalies in other parts of the skeleton may be present. This report draws attention to rare or previously undescribed localised epiphyseal bone dysplasias. We describe a family with only big toes involvement, two boys with the disorder confined to distal tibial epiphyses and one boy with selective elbows dysplasia.

Key words: bone dysplasia - big toe - elbow - tibia - epiphysis.

Localised bone dysplasias (LBD) are a group of disorders in which one anatomical area is involved. Whereas some LBD are relatively common and well publicized, other and rare, not well known or have not yet been reported. We describe six cases with three different localised epiphyseal bone dysplasias (LEBD) - one patient with localised elbows involvement, two patients with localised distal tibial epiphysis flattening and a family with dysplasia confined to the metatarso-phalangeal joint of the big toe.

Case report

Case I.

11 year-old boy presented for orthopaedic consultation because of marked valgus deformity of the feet. The height of the boy was normal. The family history was non contributory. Radiograms of the feet showed flattening and wedging of the distal tibial epiphyses (Fig. I >). Those of the knees and hips were normal.

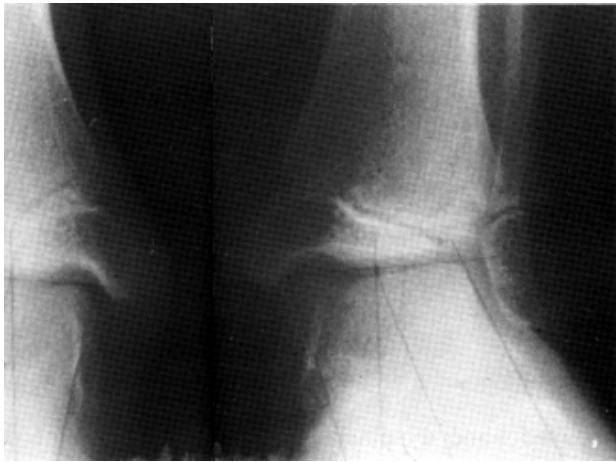

Fig. 1: Case L Boy 11 year-old. Flattened and wedged laterally distal tibial epiphyses with fragmentation of the left one.

Case II.

13 year-old boy presented for orthopaedic consultation because of pain of his right ankle for one month. For several months he had been distorting his right shoe and his mother was keen to get an arch support from a surgical firm to treat that. He was otherwise well. His height (143 cm) and weight were normal. He was not active in sport. The family history was negative. The routine blood and urine examinations serum P, Ca, serum alkaline phosphatase, urinary acid patterns, serum lead levels and methylmalonic acid screen were normal. Skeletal survey documented sclerosis, flattening and fragmentation of the distal tibial epiphyses (Fig. 2a). Sclerotic bands were present at the end of the long bone metaphyses (Fig. 2b-c). No other abnormality was seen.

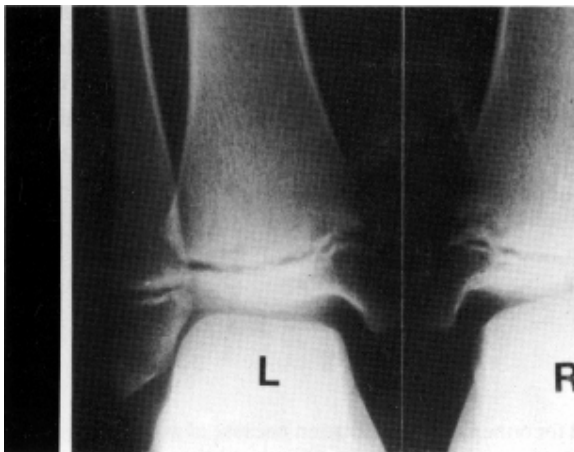

Fig. 2a: Case II. Boy 13 year-old, a: Flattened, dense distal tibial epiphyses with fragmentation of the right one. Note minor metaphyseal changes.

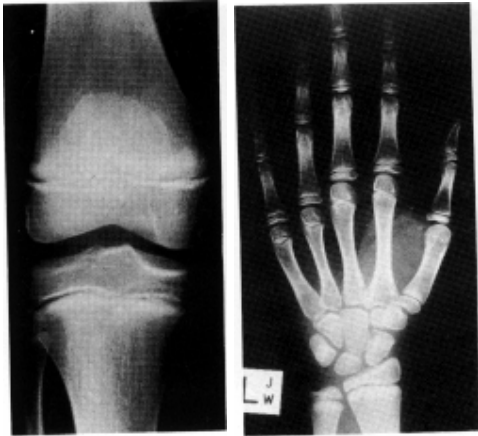


Fig. 2b-c: Dense metaphyses of the long tubular bones.

Case III.

12 year-old boy arrived for an orthopaedic consultation complaining of pain in the lateral aspect of the right elbow. Physiotherapy had made the pain worse. He had initially noticed clicking in the elbow, but that had settled and he did not describe symptoms suggestive of there being a loose body in his elbow. There was no history of locking or injury of the elbow. He had noticed an inability to fully straighten that joint in the two weeks prior to the consultation. His left elbow had caused him similar, but much less troublesome, pain and he had not noted any inability to extend that elbow. On examination, his elbow had, on the right side, a range of motion from 30-120, on the left side from full extension to 140. Both elbows had full pronation and supination. The right elbow was slightly swollen postero-laterally but had no tenderness. The elbow was stable to stress and there were no associated neurovascular problems. The left elbow was unremarkable to examination. Skeletal survey documented moderate dysplastic /hypoplastic changes in both the elbows, more marked on the right (Fig. 3a-b). No other abnormality was seen. The family history was negative. He had not been active in sport and did not use drilling tools.

Case IV.

A girl aged 2 10/12 presented for genetic consultation because of short stature. Her height was 88.5 cm, weight 12 kg. The physical examination was normal apart from minimal hypotrophy and slight lateral deviation of the big toes. At the age of 6 1/2 years her height was 108 cm.

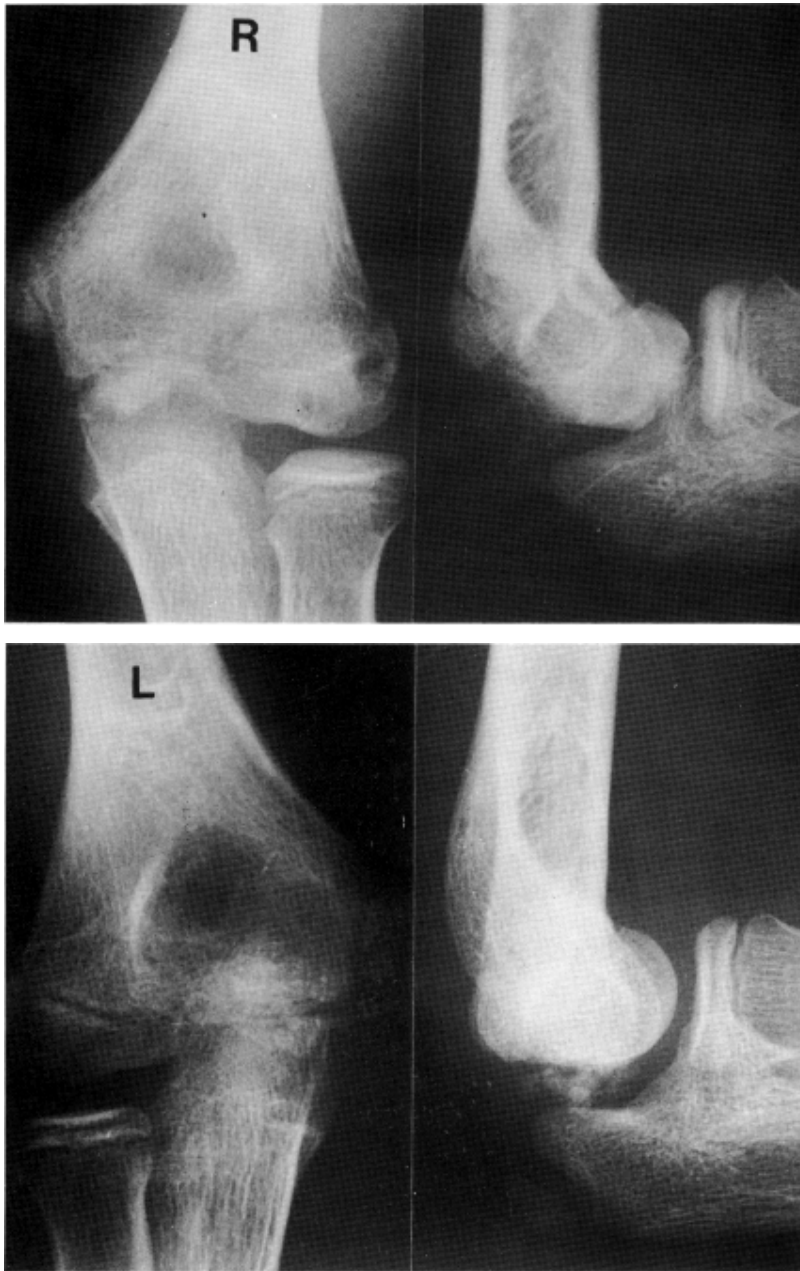

Fig. 3a-b: Case III. Boy 12 year-old. Hypoplastic / dysplastic changes at the elbow epiphyses. The right elbow is more severely affected.

The family history revealed that both her mother and grandmother were short - 140 cm and 137 cm respectively. The physical examination of the mother was normal apart from lateral deviation of the toes.

Radiograms documented minor lateral deviation of the big toes with minimal medial wedging of the basal phalanx epiphysis (Fig. 4a). Foot radiograms of the mother at the age of 11 years showed

sclerosis of the epiphysis of the basal phalanx of the big toe, minor sclerosis at the end of the 1st metatarsal with abnormal trabecular pattern (Fig. 4b). Radiograms of the grandmother demonstrated advanced, symmetrical osteo-arthritic changes at the 1st metatarso-phalangeal joint with shortening of the first metatarsal and the basal phalanx (Fig. 4c).

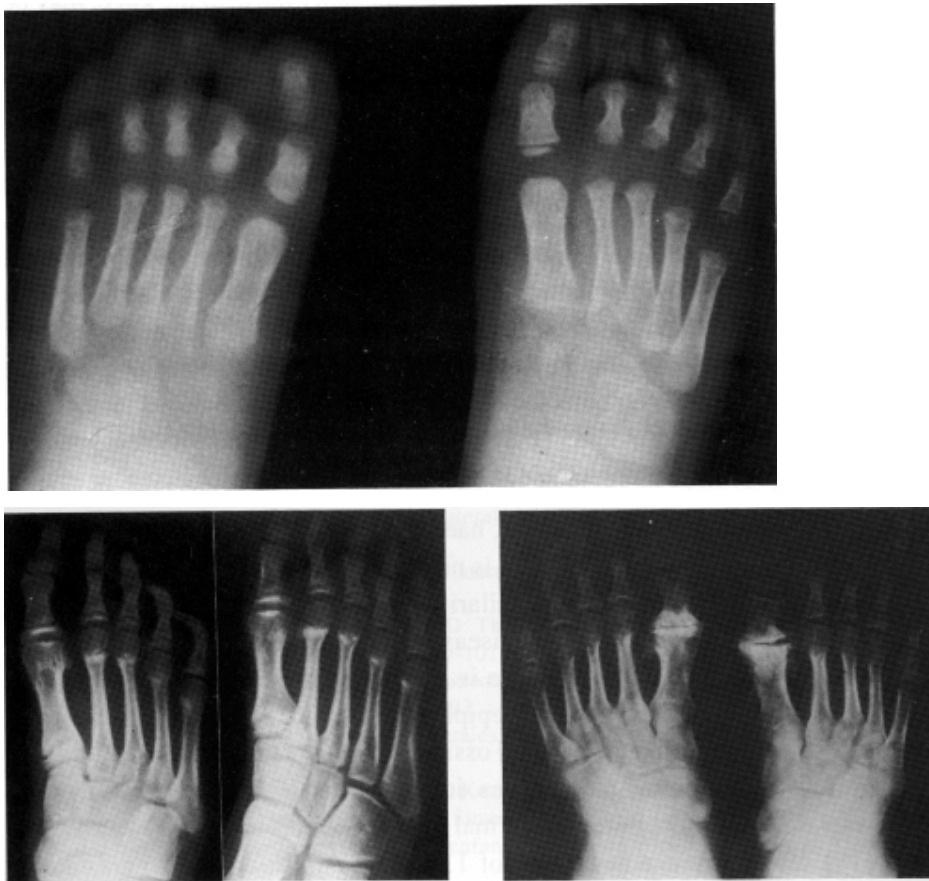


Fig. 4a-c: a: Case IV. Girl 2 10/12 year-old. Lateral deviation of the great toe. Minimal lateral narrowing of the epiphysis of the basal phalanx of the great toe.

b: Mother of A, at the age of 11 1/2 years. Minor lateral deviation of the 1st toe. Sclerosis of the epiphysis of the basal phalanx of the 1st toe and the articular surface of the head of the 1st metatarsal.

c: Grandmother of A. Severe, symmetrical osteoarthritic changes in the 1st metatarso-phalangeal joint with shortening of the adjacent phalanges.

Discussion

LBD are not so rare but are infrequently perceived. The most common and best known are congenital, bilateral glenoid hypoplasia [3, 6], isolated femoral head dysplasia [2, 10] and brachyolmia [13]. Less common are unilateral carpal dysplasia [5, 7] and LEBD of the elbows [11]

and LBD of the spine [4, 12]. The LEBD of the elbows is characterised by hypoplastic / dysplastic changes in the elbow epiphyses and often by osteochondritis dissecans. The disorder is usually bilateral and other epiphyses, especially those of the knee, may be mildly affected. A patient with bone dysplasia localised to the spine was reported as "generalised Scheuermann's disease" [4]. The height of the vertebral bodies in the latter disorder is normal. Minor capital femoral epiphyses involvement may be present. No cases of LEBD of the distal tibial epiphyses has yet been reported. There was no evidence of excessive trauma or stress to the distal tibial epiphyses in our patients.

LEBD of the distal tibial epiphyses must be differentiated from pseudotibiotalar slant which is a positioning artifact produced by examining the ankle joint in slight external rotation with flexion of the knee [11. The ankles of our patients were performed in standard AP projection. The tibial slant is minimal and the distal tibial epiphyses are flattened, sclerotic and fragmented on the left in Case I and on the right in Case II. There is also some irregularity and sclerosis of the adjacent metaphyses in Case II (Fig. I a). The changes were more marked in the older boy. Tibiotalar slant - angled configuration of the ankle mortice - does occur in multiple epiphyseal dysplasia, haemophilia, juvenile rheumatoid arthritis and sickle cell anaemia [8]. There is no evidence of any of those disorders in our Case I and II. There is some similarity between bony involvement in our patients and aseptic necrosis, Perthes disease and osteochondritis dissecans. We believe that in all these disorders there is a common vascular etiology. As no histological studies of the involved epiphyses have been performed in our patients, primary chondroid growth and ossification process cannot be excluded. The significance of dense metaphyses in our Case II is uncertain. Dense metaphyses do occur in children as normal growth variant in the first few years of life [14]. Its occurrence at the age of 13 years is unusual. We do not know what is the significance of this finding. There was no history of excessive sport activity, heavy metal poisoning or any other disorder like hypercalcaemia, Vit D poisoning which may cause dense metaphyses. The Pb serum levels were normal Symptomatic metaphyseal sclerosis in three children overlapping with plasma-cell osteomyelitis and chronic multifocal osteomyelitis was reported in 1993 [9]. In the family with lateral deviation of the 1st toe in childhood and severe osteoarthritic changes later in life the disease is inherited as an autosomal dominant trait. Osteoarthropathy of the 1st toe affecting the metatarso-phalangeal joint occurs in diabetes, congenital indifference to pain and gout. There were no clinical signs suggestive of any of those disorders and the radiographic appearances of the big toe are different. The changes are asymmetrical, often multifocal and usually accompanied by bone destruction and osteoporosis. Family history may be useful in selective cases.

Conclusion

We report six children with LEBD. That of the distal tibial epiphyses and great toe has not yet been reported. This paper expands our knowledge and draws attention to the problem of LBD.

References

1. Bigongiari LR: Pseudotibiotalar slant: a positioning artifact. *Radiology* 22:669-670, 1977.
2. Cilliers HJ, Beighton P: Beukes familial hip dysplasia: an autosomal dominant entity. *Am J Med Genet* 36:386-390, 1990.
3. Currarino G, Sheffield E, Twickler D: Congenital glenoid dysplasia. *Pediatr Radiol* 28:30-37, 1998.
4. Kozłowski K, Pienkowska-Mikolajczyk J: Przypadek postaci uogólnionej choroby Scheuermanna u chłopca 12 letniego. *Chir Narz Ruch Ortop PoIs* 27:653-656, 1962.
5. Kozłowski K, Pietron K: Familial X-linked unilateral carpal hypoplasia hypoplasia/dysplasia - a new syndrome. Report of four cases. *Pediatr Radiol* 19:261-262, 1989.
6. Kozłowski K, Scougall J: Congenital bilateral glenoid hypoplasia: a report of four cases. *Brit J Radiol* 60:705-706, 1987.
7. Krauss CM, Herman TE, Holmes LB: Unilateral carpal bone deformity in mother and son. *Am J Med Genet* 26:557-563, 1987.
8. Leichtman DA, Bigongiari LR, Wicks JD: The incidence and significance of tibiotalar slant in sickle cell anemia *Skeletal Radiol* 3:99-101, 1978.
9. Lord P, Carty HML: Case report: Unexplained symptomatic metaphyseal sclerosis in children: three cases. *Brit J Radiol* 66:737-740, 1993.
10. Maroteaux P, Hedon C: Dysplasies bilaterales isolees de la hanche chez le jeune enfant. *Ann Radiol* 24:181-187, 1981.
11. Maroteaux P, Wiedemann R, Spranger J, Kozłowski K, Lenzi L: Essai de classification des dysplasies spondylo-epiphysaires. Lyon, Simep 1968.
12. Maroteaux P: Les maladies osseuses de l'enfant. 3-e Edition. *Medicine-Sciences*. Flammarion 1995. pp 111-112.
13. Shohat M, Lachman R, Gruber HE, Rimoin DL: Brachyolmia: radiographic and genetic evidence of heterogeneity. *Am J Genet* 33:209-219.

14. Silverman FN: Caffey's Pediatric X-Ray Diagnosis. 7-th Edition. Year Book Medical Publishers, Chicago 1985. pp 481.

Dr. K. Kozlowski

New Children's Hospital

PO Box 3515

Parramatta 2124, Australia